

First Report of *Acanthocheilonema spirocauda* in the Mediterranean Monk Seal (*Monachus monachus*)

E. Papadopoulos,^{1,5} P. Loukopoulos,² A. Komnenou,³ E. Androukaki,⁴ and A. A. Karamanlidis⁴

¹ Laboratory of Parasitology and Parasitic Diseases, Faculty of Veterinary Medicine, Aristotle University, 54124 Thessaloniki, Greece; ² Laboratory of Pathology, Faculty of Veterinary Medicine, Aristotle University, 54124 Thessaloniki, Greece; ³ Exotic Animal and Wildlife Unit, Clinic of Companion Animals, Faculty of Veterinary Medicine, Aristotle University, St. Voutyra 11, 546-27 Thessaloniki, Greece; ⁴ MOm/Hellenic Society for the Study and Protection of the Monk Seal, 18 Solomou St, 10682 Athens, Greece; ⁵ Corresponding author (email: eliaspap@vet.auth.gr)

ABSTRACT: The Mediterranean monk seal (*Monachus monachus*) is one of the world's most endangered marine mammals. The largest population is located mainly throughout the Aegean and Ionian islands and along the coastline of southern continental Greece. We report the findings of a necropsy and discuss their potential importance to the conservation of the species. The adult female monk seal appeared to be in a good nutritional state. The main necropsy findings were injuries consistent with a violent and sudden death, including three round wounds on the ventral surface of the body and several hematomas, as well as a decomposing male fetus in the uterus. Two nematodes were found in the right ventricle of the heart; no abnormalities were observed in the lungs, pulmonary vessels, or heart. The nematodes were identified as *Acanthocheilonema spirocauda*. This is the first report of infection of the Mediterranean monk seal with *A. spirocauda*, even though this is the most common heartworm found in most pinnipeds worldwide. This parasite should be considered in health care monitoring projects of this endangered species.

Key words: *Acanthocheilonema spirocauda*, conservation, endangered species, Greece, *Monachus monachus*, monk seal.

Diseases, such as those caused by parasites or viruses, can have various effects on marine wildlife, ranging from grossly nondetectable pathologic findings to regulation of entire populations (Gulland, 1995; Raga et al., 1997). In endangered animals, diseases may constitute the single greatest threat to a species' survival (Primack, 1998). The Mediterranean monk seal (*Monachus monachus*) is the world's rarest seal and, with fewer than 600 individuals surviving (Johnson et al., 2006), is one of the most endangered marine mammals (IUCN, 2007). In 1997, a mass die-off affected the species' largest

surviving colony in the Western Sahara; a morbillivirus is considered to have been a potential causative agent of this die-off (Osterhaus et al., 1998). Since then, and despite the recognition of the effect diseases can have on the conservation of the Mediterranean monk seal and the necessity to closely monitor the health status of the species (Johnson et al., 2006), little effort has been invested in this direction (van de Bildt et al., 2000; Toplu et al., 2007). Herein, we report the findings of a necropsy of a Mediterranean monk seal and discuss their potential importance to the conservation of the species.

A dead Mediterranean monk seal was reported on 16 May 2006 to the Hellenic Rescue and Information Network (Adamantopoulou et al., 1999). The seal was found at Neos Marmaras (40°05'35.79"N, 23°47'16.24"E), in the prefecture of Chalkidiki, and transported to the Aristotle University of Thessaloniki, where a full necropsy was performed according to a specific necropsy protocol for pinnipeds (Winchell, 1990). On arrival, the carcass was severely decomposed, to a degree that allowed the identification of internal structures, but not the complete identification or detailed description of possible lesions present.

The seal was an adult female (standard length=240 cm) in good nutritional state (blubber thickness at pelvis=5.8 cm, at thorax=8 cm). Several small skin ulcerations found on the body externally multifocally likely occurred postmortem. Three round wounds were observed on the ventral side of the body. Two of the wounds were 2.5 cm in diameter; the

third was slightly larger and was approximately 10 cm caudal to the umbilicus on the midline, with the abdominal organs partially protruding from it. A large hematoma was observed at the muscles of the right axilla, and two smaller hematomas involved the subcutaneous tissues in the abdominal area. A large amount of unclotted blood was present focally in the right cranial area of the peritoneal cavity. Several small whitish foci were present on the pericardium. Two nematodes found in the right ventricle of the heart were placed in ethanol and kept for identification. No other parasites were observed in the heart, lungs, pulmonary vessels, or anywhere else in the body, following careful inspection. No microscopic parasitologic examination was done. Skin and tissue samples collected from the blubber and several internal organs are undergoing toxicologic, virologic, genetic, and stable isotope analysis by the Hellenic Society for the Study and Protection of the Monk Seal. The stomach was removed and dietary analysis carried out (Pierce et al., 2009). The gall bladder contained a small amount of bile and the stomach contained undigested food. The genital orifice was dilated and a decomposing male fetus, approximately 40 cm long, was present in the uterus. All other changes observed were considered to be postmortem.

Based on morphological criteria (Yamaguti, 1962) and location in the right ventricle of the heart, the worms recovered were identified as adult male and female *Acanthocheilonema spirocauda* (Fig. 1) filarial worms. The posterior extremity of the male (length 14 cm, width 0.055 cm) ended in three spiral coils and a digitiform tail, whereas the tail of the female (20.3×0.06 cm, location of vulva 4.5 cm from the anterior end) was short and a blunt conical shape. The description of the parasites matches published information; however, the size is larger in our case. A possible explanation for this may be the larger size of the monk seal compared to the hooded seal (Helle and

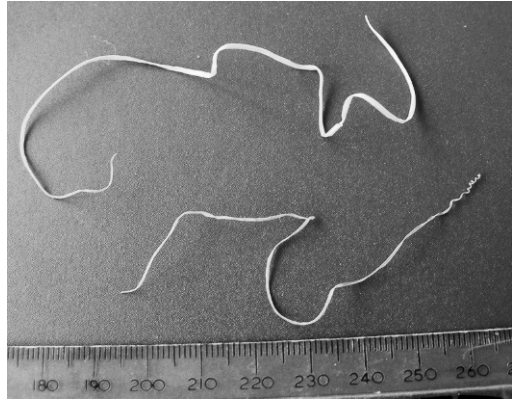


FIGURE 1. A male (lower) and female (upper) *Acanthocheilonema spirocauda* recovered from the right ventricle of the heart of an adult Mediterranean monk seal.

Blix, 1973; van der Kamp, 1987; Leidenberger and Bostrom, 2008) or that the parasite belongs to a different strain, variety, or subspecies. Genetic analysis is required to confirm this hypothesis.

Parasites identified in the Mediterranean monk seal include *Anisakis pegreffii* (Campana-Rouget and Biocca, 1955), *Contracaecum* sp., *Diphyllbothrium* sp. (Schnapp et al., 1962), and *Lepidophthirus piriformis* (Blagoveshtchensky, 1966). Ours is the first report of infection of the species with *A. spirocauda*. This parasite is one of the most common heartworms in pinnipeds worldwide (Haebler and Moeller, 1992); it causes mortality mainly among juvenile seals, whereas adult seals generally tolerate parasite burdens and are adversely affected by them only in the presence of secondary infection or immunocompromised condition (Stroud and Dailey, 1978; Haebler and Moeller, 1992).

Although the life cycle of *A. spirocauda* is not fully known, this parasite has been found in numerous species of Arctic pinnipeds, including *Phoca hispida*, *Phoca vitulina*, *Phoca groenlandica*, and *Cystophora cristata*, mainly in the right ventricle (Eley, 1981; Measures et al., 1997). Our findings are similar in that both

worms were recovered from the right ventricle. Both sexes may be found together, as in our case (Macdonald and Gilchrist, 1969); in other cases, only one sex was found, although other worms may have been present that had not reached the heart (Eley, 1981).

The presence and impact of parasites on their hosts can be influenced by environmental stressors, such as pollution, habitat alteration, and fisheries (Lafferty and Kuris, 1999). In a rapidly changing environment, such as the eastern Mediterranean Sea, all these stressors have an effect on the survival of Mediterranean monk seals (Johnson et al., 2006, Borrell et al., 2007, Karamanlidis et al., 2008). The survival of the species will depend on the preservation of both terrestrial and marine habitat, as well as the maintenance of the population in good health. Infection by *A. spirocauda* should be considered in future health care monitoring projects for Mediterranean monk seals.

The authors thank the Municipality and Port Police authorities of Neos Marmaras for alerting MOm and facilitating the transportation of the animal to the Pathology Laboratory. Also thanks are extended to G. Brellou, A. Thomas, L. Tzourou, and other members and students of the Faculty of Veterinary Medicine for assisting during the necropsy. Partial funding was provided by the project "MOFI: Mitigating the Conflict in Greek Seas" (LIFE05NAT/GR/000083).

LITERATURE CITED

- ADAMANTOPOULOU, S., E. ANDROUKAKI, AND S. KOTOMATAS. 1999. The distribution of the Mediterranean monk seal in Greece based on an information network. *Contributions to the Zoogeography and Ecology of the Eastern Mediterranean Region* 1: 399–404.
- BLAGOVESHCHENSKY, D. I. 1966. New forms of lice (Siphunculata) parasites of pinnipeds and hares. *Entomologicheskoe Obozrenie* 45: 806–813.
- BORRELL, A., G. CANTOS, A. AGUILAR, E. ANDROUKAKI, AND P. DENDRINOS. 2007. Concentrations and patterns of organochlorine pesticides and PCBs in Mediterranean monk seals (*Monachus mon-*
- achus*) from Western Sahara and Greece. *Science of the Total Environment* 381: 316–325.
- CAMPANA-ROUGET, Y., AND E. BIOCCA. 1955. Une nouvelle espece d'*Anisakis* chez un phoque Mediterranean. *Annales de Parasitologie* 30: 477–480.
- ELEY, T. J. 1981. *Dipetalonema spirocauda* in Alaskan marine mammals. *Journal of Wildlife Diseases* 17: 65–67.
- GULLAND, F. M. D. 1995. The impact of infectious diseases on wild animal populations—A review. In *Ecology of infectious diseases in natural populations*, B. T. Grenfell and A. P. Dobson (eds.). Cambridge University Press, Cambridge, UK, pp. 20–51.
- HAEBLER, R., AND R. B. MOELLER. 1992. Pathology of selected marine mammal diseases. In *Pathobiology of marine and estuarine organisms: An overview*, J. A. Couch and J. W. Fournie (eds.). CRC Press, Boca Raton, Florida, pp. 217–244.
- HELLE, O., AND A. S. BLIX. 1973. Some morphological characteristics of *Dipetalonema spirocauda* Leidy, 1858, isolated from the hooded seal, *Cystophora cristata* Erxleben 1777. *Journal of Parasitology* 59: 217–218.
- [IUCN] INTERNATIONAL UNION FOR CONSERVATION OF NATURE. 2007. *2007 IUCN Red List of Threatened Species*. www.iucnredlist.org. Accessed December 2009.
- JOHNSON, W. M., A. A. KARAMANLIDIS, P. DENDRINOS, P. F. DE LARRINO, M. GAZO, L. M. GONZALEZ, H. GUECLUESOY, R. PIRES, AND M. SCHNELLMANN. 2006. *Monk Seal Fact Files. Biology, Behaviour, Status and Conservation of the Mediterranean Monk Seal*, *Monachus monachus*, www.monachus-guardian.org/factfiles/medit01.htm. Accessed December 2009.
- KARAMANLIDIS, A. A., E. ANDROUKAKI, S. ADAMANTOPOULOU, A. CHATZISPYROU, W. M. JOHNSON, S. KOTOMATAS, A. PAPADOPOULOS, V. PARAVAS, G. PAXIMADIS, R. PIRES, E. TOUNTA, AND P. DENDRINOS. 2008. Assessing accidental entanglement as a threat to the Mediterranean monk seal *Monachus monachus*. *Endangered Species Research* 5: 205–213.
- LAFFERTY, K. D., AND A. M. KURIS. 1999. How environmental stress affects the impacts of parasites. *Limnology and Oceanography* 44: 925–931.
- LEIDENBERGER, S., AND S. BOSTROM. 2008. Characterization of the heartworm *Acanthocheilonema spirocauda* (Leidy, 1858) Anderson, 1992 (Nematoda: Onchocercidae) in Scandinavia. *Parasitology Research* 104: 63–67.
- MACDONALD, D. W., AND E. W. GILCHRIST. 1969. *Dipetalonema spirocauda* and *Pseudomonas aeruginosa* infection in a harbor seal. *Canadian Veterinary Journal* 10: 220–221.
- MEASURES, L. N., J. F. GOSSELIN, AND E. BERGERON. 1997. Heartworm, *Acanthocheilonema spiro-*

- cauda* (Leidy, 1858), infections in Canadian phocid seals. *Canadian Journal of Fisheries and Aquatic Sciences* 54: 842–846.
- OSTERHAUS, A., M. VAN DE BILDT, L. VEDDER, B. MARTINA, H. NIESTERS, J. VOS, H. VAN EGMOND, D. LIEM, R. BAUMANN, E. ANDROUKAKI, S. KOTOMATAS, A. KOMNENOU, B. A. SIDI, A. B. JIDDOU, AND M. E. O. BARHAM. 1998. Monk seal mortality: Virus or toxin? *Vaccine* 16: 979–981.
- PIERCE, G. J., G. HERNANDEZ, B. M. SANTOS, A. EDRIDGE, P. DENDRINOS, M. PSARADELLI, E. TOUNTA, AND E. ANDROUKAKI. 2009. Diet of Mediterranean monk seals (*Monachus monachus*). In 23rd annual conference of the European Cetacean Society: Climate change and marine mammals, Turkish Marine Research Foundation, Istanbul, Turkey, 2–4 March 2009, pp. 129–130.
- PRIMACK, R. 1998. *Essentials of conservation biology*. Sinauer Associates, Sunderland, Massachusetts, 660 pp.
- RAGA, J. A., J. A. BALBUENA, J. AZNAR, AND M. FERNANDEZ. 1997. The impact of parasites on marine mammals: A review. *Parassitologia* 39: 293–296.
- SCHNAPP, B., S. HELLWING, AND G. GHIZELEA. 1962. Contributions to the knowledge of the Black Sea seal (*Monachus monachus*) Herm. *Travaux du Museum d'Histoire Naturelle "Gr. Antipa"* 3: 383–400.
- STROUD, R. K., AND M. D. DAILEY. 1978. Parasites and associated pathology observed in pinnipeds stranded along the Oregon coast. *Journal of Wildlife Diseases* 14: 292–298.
- TOPLU, N., A. AYDOGGAN, AND T. C. OGUZOGU. 2007. Visceral leishmaniosis and parapoxvirus infection in a Mediterranean monk seal (*Monachus monachus*). *Journal of Comparative Pathology* 136: 283–287.
- VAN DE BILDT, M. W. G., B. E. E. MARTINA, E. J. VEDDER, E. ANDROUKAKI, S. KOTOMATAS, A. KOMNENOU, B. A. SIDI, A. B. JIDDOU, M. E. O. BARHAM, H. G. M. NIESTERS, AND A. D. M. E. OSTERHAUS. 2000. Identification of morbilliviruses of probable cetacean origin in carcasses of Mediterranean monk seals (*Monachus monachus*). *Veterinary Record* 146: 691–694.
- VAN DER KAMP, J. S. 1987. Pulmonary diseases in seals—A histopathological review. *Aquatic Mammals* 13: 122–124.
- WINCHELL, J. M. 1990. Field manual for phocid necropsies (specifically *Monachus schauinslandi*). National Oceanic and Atmospheric Administration, National Marine Fisheries Service, Southwest Fisheries Science Center, Honolulu, Hawaii, 55 pp.
- YAMAGUTI, S. 1962. *Systema helminthum*, Vol. 3. The nematodes of vertebrates. Interscience Publishers, London, UK, pp. 1261.

Received for publication 14 January 2009.